

**CASE STUDY**

# Genetic Testing Alerts Patient to the Risk of Future Cardiac Arrhythmia

How many of us can associate a cardiac arrest with a 11-year-old boy? Cardiac events are not part of a child's world and neither should they be. Yet, for 11-year old Karthik, an unexpected turn of events led to the discovery of his risk for irregular heartbeats (arrhythmias) resulting from an inherited genetic mutation.

## Patient Profile

Karthik\*, aged 11, was scheduled to undergo a surgery to get his appendix removed. During the surgery, the child suffered a cardiac arrest. Although he was revived, the incident was alarming enough for his doctors and parents to investigate the cause of the heart attack.

## Medical Investigations

An ECG (electrocardiogram) revealed that Karthik had an irregular heartbeat, a condition known as 'long QT' syndrome in medical parlance. Contractions of the heart are regulated by a series of electrical signals that are delivered as characteristic pulses. Each phase of this pulse is designated by the letters P, Q, R, S, T (See fig 1).

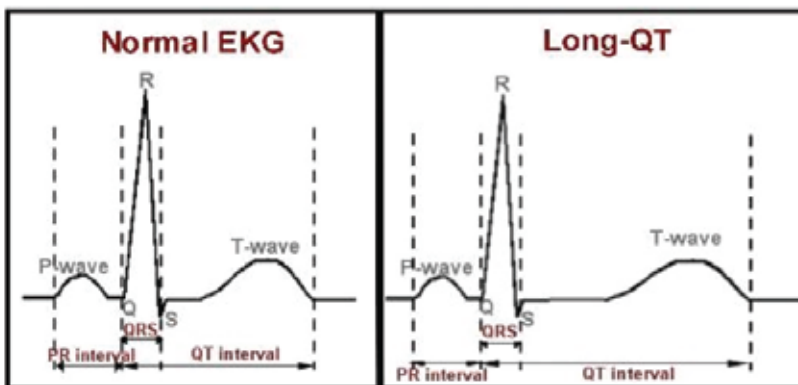


Figure 1. Normal and Long-QT ECG recordings

The time interval between the Q and T electrical pulses in normal individuals is 0.35-0.43s, which is one-third of the total time of the heartbeat. In individuals suffering from long QT syndrome, this interval lasts for longer than 0.43s. Essentially, this results in an irregular heartbeat. Individuals with long QT syndrome are prone to experiencing arrhythmias triggered by sudden emotional stress like fright or by physical exertion.

Genetic testing was advised to Karthik's parents to understand the sudden cardiac arrest during his appendectomy.

## Genetic Counseling

Karthik's family history was recorded during a genetic counselling session. Karthik has an elder brother (23 years). Both brothers are born to parents in a non-consanguineous marriage. His parents had aborted two additional pregnancies, owing to the incidence of fetal brain abnormalities.

Karthik's father (age 50 years) had suffered from a heart attack in the preceding years with a resultant angioplasty performed on him. Other family members, like aunts and grandparents, did not have a history of cardiac ailments.

\* Name changed to protect patient privacy



**Patient:** 11-year old boy

**Gender:** Male

**Key Findings:**  
Long QT syndrome confirmed in patient  
Genetic testing established his risk for future cardiac arrest

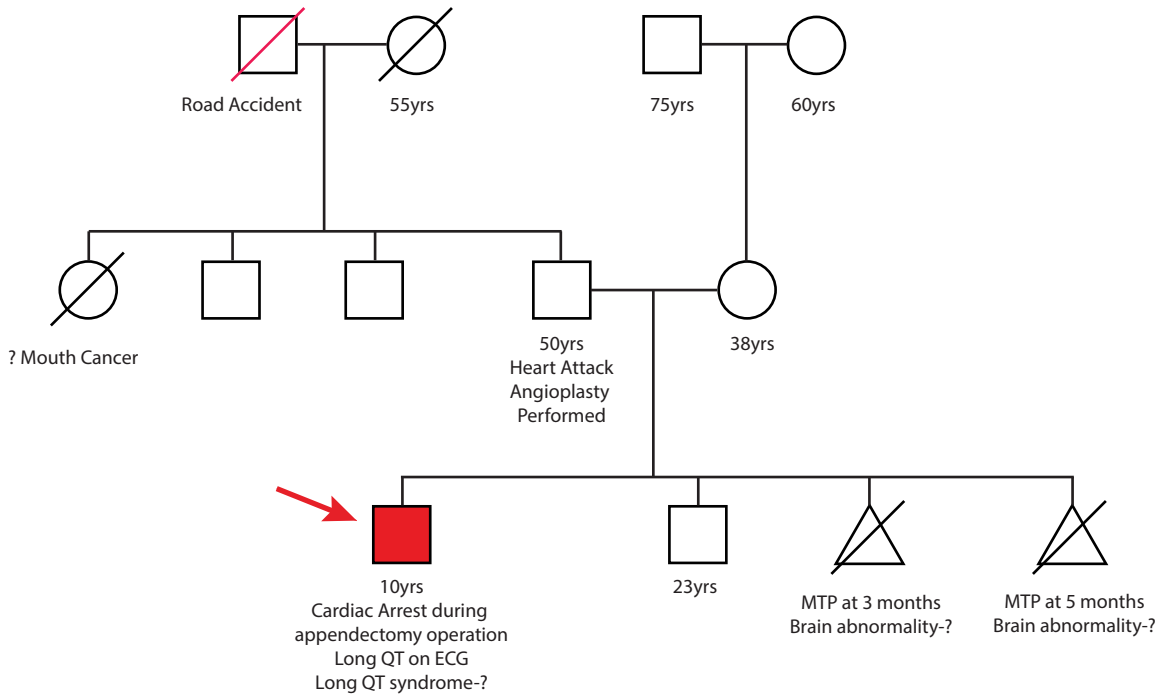


Figure 2: Family History of Proband Presenting with Long QT syndrome

The Strand Clinical Exome test was advised in this case to investigate the genetic causes of long QT syndrome.

## Results of Genetic Testing

A 'likely pathogenic' mutation of the *KCNQ1* gene was identified in Karthik's genome.

Mutations in *KCNQ1* are associated with long QT syndrome type 1 (Giudicessi & Ackerman 2013; Adadi et al. 2017) and are inherited in an autosomal dominant manner. This means that only one defective (mutant) copy of this gene is sufficient for causing the long QT syndrome in this patient. Consequently, heterozygous individuals, which have only one copy of the mutant gene can also suffer from long QT syndrome despite inheriting a second, normal copy of this gene.

**RESULT**



Positive For a heterozygous 'likely pathogenic' variant in exon 15 of the *KCNQ1* Gene

### Key Findings

Gene	Variation	Zygoty	Clinical significance
<i>KCNQ1</i>	chr11:2799241G>A c. 1768G>Ap.Ala590Thr	Heterozygous	Likely Pathogenic

## Conclusions

- o Karthik was found to be heterozygous for a likely pathogenic variant of the *KCNQ1* gene, thereby establishing the genetic cause of his long QT syndrome.
- o Counselling was provided to him and his parents to avoid the incidence of cardiac arrests in the future.
- o Mutation-specific testing was advised to his parents to understand whether his parents were also heterozygous for this mutation or not. Genetic testing of both parents could have led to an understanding of the risk of cardiac arrest, for them as well.

## Strand Clinical Exome Test

The Strand Clinical Exome test includes genes involved in inherited cardiological disorders. The test is a comprehensive test that can assay for > 4500 genes.

## References

- Adadi, N. et al., 2017. Clinical and molecular findings in a Moroccan family with Jervell and Lange-Nielsen syndrome: a case report. *Journal of Medical Case Reports*, 11(1), p.88. Available at: <http://www.ncbi.nlm.nih.gov/pubmed/28364778> [Accessed May 10, 2017].
- Giudicessi, J.R. & Ackerman, M.J., 2013. Genotype- and phenotype-guided management of congenital long QT syndrome. *Current problems in cardiology*, 38(10), pp.417–55. Available at: <http://www.ncbi.nlm.nih.gov/pubmed/24093767> [Accessed May 9, 2017].

